

Primitive Reflexes and Postural Reactions in the Neurodevelopmental Examination

Dimitrios I. Zafeiriou, MD, PhD

The primitive reflexes and the postural reactions comprise one of the earliest, simplest, and most frequently used tools among child neurologists to assess the central nervous system integrity of infants and young children. Infants with cerebral palsy have been known to manifest persistence or delay in the disappearance of primitive reflexes and pathologic or absent postural reactions. The clinical significance of asymmetric tonic neck reflex, Moro, palmar grasp, plantar grasp, Galant, Babinski, Rossolimo, crossed extensor, suprapubic extensor, and heel reflex, alone or in combination, as well as their contribution to the early diagnosis and differential diagnosis of cerebral palsy, have been demonstrated in a number of studies. Moreover, infants with 5 or more abnormal postural reactions have developed either cerebral palsy or developmental retardation as reported in a number of studies. Although a comprehensive neurologic examination in the context of a motor assessment instrument is preferable to an informal list of items, the combined examination of primitive reflexes and postural reactions should be considered by the child neurologist, as a simple but predictive screening test for the early identification of infants at risk for cerebral palsy. It is quick and easy to perform, both in nonhospital environments and in underdeveloped countries, where time and specific recourses are limited. The combined examination is also useful in developed countries because many developmental disorders such as cerebral palsy appear in nonrisk groups whereas others are not detected by metabolic screening programs. © 2004 by Elsevier Inc. All rights reserved.

Zafeiriou DI. Primitive reflexes and postural reactions in the neurodevelopmental examination. *Pediatr Neurol* 2004;31:1-8.

Introduction

The primitive reflexes and the postural reactions constitute one of the earliest, simplest, and most frequently used tools among child neurologists, as well as developmental and general pediatricians all over the world to assess the central nervous system integrity of infants and young children [1]. On the other hand, there are a considerable number of developmental scales [2-8], developmental screening tests [9-15], and motor assessment instruments [16-20] which more or less cope with the evaluation of motor development in either term or preterm infants and young children and include a variable number of primitive reflexes or postural reactions as items [21] (Table 1). The reliability, sensitivity, and validity of some of these motor assessment instruments vary greatly, and each one's predictive power increases with the age of the infant or young child [22]. Moreover, in a critical review by Majnemer and Mazer, none of the instruments tested was effective in the early diagnosis of infants younger than 12 months of age [23]. Although a comprehensive neurologic examination is preferable than an informal list of items, either in the busy neuropaediatric daily practice or even at the hospital, it is crucial to obtain as much information as possible within a small time frame.

The purpose of the current article is to review and critically discuss the major primitive reflexes and postural reactions as an integral part of the neurologic examination of the infant. This review will also summarize the diagnostic relevance of specific primitive reflexes or postural reactions, alone or in combination, regarding an early diagnosis of cerebral palsy and developmental retardation. Furthermore, the diagnostic utility of the presence of primitive reflex patterns in adults with various neurologic disorders will be outlined. Finally, the assessment of general movements, a promising new diagnostic tool for the neurologic examination of high-risk infants based on

Table 1. Most commonly used motor performance tools (References for each are given in brackets)

A. Developmental Scales
Amiel-Tison [2]
Bayley [3]
Brazelton [4]
Dubowitz [5]
Haataja [6]
Peabody [7]
Prechtl [8]
B. Developmental Screening Tests
Denver Developmental Screening Test (Denver II) [9]
Battelle Screening Test [10]
Clinical Adaptive Test (CAT)/Clinical Linguistic and Auditory Milestone Scale (CLAMS) [11]
Knobloch Revised Screening Inventory [12]
General Movements (GMs) Assessment [13-15]
C. Motor Assessment Instruments
Alberta Infant Motor Scale (AIMS) [16]
Early Motor Pattern Profile (EMPP) [17]
Gross Motor Function Measure (GMFM) [18]
Movement Assessment Inventory (MAI) [19]
Test of Infant Motor Performance (TIMP) [20]

the observation of spontaneous motility, will be briefly discussed.

Primitive Reflexes

Primitive reflexes are brainstem-mediated, complex, automatic movement patterns that commence as early as the twenty-fifth week of gestation, are fully present at birth in term infants, and with central nervous system maturation become more and more difficult to elicit after the first half of the first year of life, when voluntary motor activity and thus cortical inhibition emerges and takes over [24-26]. They are considered part of the motor repertoire of the specific age. Primitive reflexes are highly stereotypical patterns and are elicited by specific sensory stimuli.

The major primitive motor reflexes or patterns that have been described include Moro, palmar and plantar grasp, rooting, sucking, placing, Moro, Galant (or truncal incurvation), asymmetric tonic neck reflex, crossed extensor, tonic labyrinthine reflex, and others [21]. Some authors make no distinction between primitive reflexes and postural reactions (i.e., primitive and postural behaviors); there is an ongoing controversy concerning the ones that, alone or in combination, have the greatest predictive clinical significance. For example, Capute [27], in a long-term follow-up study, regards the Galant reflex among the major predictive primitive reflexes being extensively evaluated. Dargassies [13], on the other hand, believes the crossed extensor reflex to be most critical for central nervous system maturation. Gupta [28] selects plantar, palmar, rooting, Moro, crossed extensor, tonic labyrinthine reflex, Landau, placing, and positive support without a clear distinction between reflexes and reactions.

The revised Dubowitz scale [5] uses the palmar and plantar grasp, Moro, suck, and placing reflex. Scherzer again finds more clinically relevant the Moro, palmar and plantar grasp, asymmetric tonic neck reflex, rooting and sucking reflex [21]. Mandich et al. [29] compiled a developmental test (not listed in Table 1) extrapolating data from the Denver Developmental Screening Test and the Bayley scales, which mixed primitive reflexes with postural reactions and developmental milestones and included plantar grasp reflex, asymmetric tonic neck reflex, tonic labyrinthine reflex, neck righting reflex, Landau reaction, and parachute reaction. Futagi et al. [30] and Zafeiriou et al. [31], both drawing on the work of Vojta [32], place greater emphasis on the following eight reflexes: palmar and plantar grasp response, crossed extensor, suprapubic extensor, Galant, asymmetric tonic neck reflex, heel, and Rossolimo reflex. Moreover, Zafeiriou et al. [33] underscore the importance of eliciting a true Babinski response by eliciting the plantar response in infancy, as well as the importance of the Moro reflex [34]. Almost all of these investigators used the same method of eliciting reflexes, thus indicating the validity of the method used (Table 2). This consistency in terminology and concept (especially method of elicitation but also grading) was already evident in the work of Paine [35] and Towne [36], but was systematically advocated by Capute [27], thus avoiding oversimplifications or even discrepancies in method of elicitation. Simultaneously with Holt [37] and Molnar [38], Capute introduced the concept of "obligatory reflexes" (or 4+ primitive reflex) [39]. The latter is defined as a fixed response or posture when the stimulus is initiated and for as long as the stimulus persists, until it is removed.

Special emphasis should be placed on the plantar response of the infant, which is a polysynaptic response elicited by stroking along the lateral aspect of the foot from heel to toe [40]. Different types of responses have been elicited in infants, varying from flexor to extensor according to the intensity of the stimulus used [33]. It is generally accepted [41,42] that extensor plantar response matures to flexor by the end of the first year in most normal infants. The Babinski sign refers to the extensor toe response observed in diseases involving the corticospinal tract in older children and adults, and is considered by many authorities as the single most useful clinical reflex in neurology [43]. However, there is an ongoing controversy whether a true Babinski sign (dorsiflexion of the great toe and fanning of the remaining toes) obtained by eliciting the plantar response is present in infants in the context of a primitive reflex. According to some authors, a true Babinski response denotes dysfunction of the pyramidal tract and should be clearly distinguished from extensor toes that do not belong to the flexion synergy of the leg [43] and constitute a primitive reflex of the infant. In the same context, Fenichel [44] uses the withdrawal reflex, which is produced by a noxious stimulus to the sole of one foot and causes flexion of the stimulated limb and

Table 2. Eliciting the primitive reflexes according to references [30-34] and [54]

Reflex	Position	Method	Response	Age at Disappearance
Palmar grasp	Supine	Placing the index finger in the palm of the infant	Flexion of fingers, fist making	6 months
Plantar grasp	Supine	Pressing a thumb against the sole just behind the toes in the foot	Flexion of toes	15 months
Galant	Prone	Scratching the skin of the infant's back from the shoulder downwards, 2-3 cm lateral to the spinous processes	Incurvation of the trunk, with the concavity on the stimulated side	4 months
Asymmetric tonic neck reflex	Supine	Rotation of the infant's head to one side for 15 s	Extension of the extremities on the chin side and flexion of those on the occipital side	3 months
Suprapubic extensor	Supine	Pressing the skin over the pubic bone with the fingers	Reflex extension of both lower extremities, with adduction and internal rotation into talipes equinus	4 weeks
Crossed extensor	Supine	Passive total flexion of one lower extremity	Extension of the other lower limb with adduction and internal rotation into talipes equinus	6 weeks
Rossolimo	Supine	Light tapping of the 2nd-4th toes at their plantar surface	Tonic flexion of the toes at the first metacarpophalangeal joint	4 weeks
Heel	Supine	Tapping on the heel with a hammer, with the hip and knee joint flexed, and the ankle joint in neutral position	Rapid reflex extension of the lower extremity in question	3 weeks
Moro	Supine	Sudden head extension produced by a light drop of the head	Abduction followed by adduction and flexion of upper extremities	6 months
Babinski	Supine	Striking along the lateral aspect of the sole extending from the heel to the head of the fifth metatarsal	Combined extensor response: simultaneous dorsiflexion of the great toe and fanning of the remaining toes	Presence always abnormal

extension of the contralateral limb. The flexion part of the withdrawal reflex can be demonstrated in a considerable number of infants while trying to elicit the plantar response.

Postural Reactions

A number of postural reactions (i.e., motor patterns) have been identified and repeatedly described as diagnostically relevant. Both Capute et al. [45] in the English literature and Vojta [32] in the German literature emphasized the distinction between primitive reflexes and postural reactions. Blasco [26,46] and the Kennedy group (Capute et al. from the John F. Kennedy Institute in Baltimore) [45] suggested that postural mechanisms are not true reflexes, but rather are based on multiple input modalities, usually acting as a whole; they further suggested that postural mechanisms require cortical integrity and thus are not present in the neonate, but instead develop postnatally, being considered mature postural responses that persist as a basis for normal motor behavior.

It was Vojta [32] who first underlined the theory that postural reactions are present at birth and follow the stages of postural ontogenesis. Their mature response is elicited at the age that Capute et al. [45] and other investigators [26,46] describe and is qualitatively equivalent to the latter. Vojta slightly modified six already known postural reactions and, together with a new one that he first

described, used them as a set of seven items which could serve as a motor screening test [32]. According to Vojta, postural responses represent complex motor responses to a plurality of afferences such as the joints, the tendons, the muscles, the skin, the inner organs, telereceptors (eye) and otoreceptors (ear), and of course the labyrinth. They are characterized by a certain stereotyped posture of the trunk, head, and extremities (i.e., the entire body), when the examiner attempts a strictly defined sudden change of position (Table 3, Fig 1). The response at each chronological age is different and expresses the central nervous system stage of maturation.

Regarding postural reactions, limited data are available on their evolution in early infancy, and they concern mostly the three righting reflexes in prone position: the tonic labyrinthine reflex, symmetric tonic neck righting, and the Landau reaction (vertical suspension) [45]. However, from Capute's study, it was clear that there are differences of opinion concerning whether the postural reactions are all absent in the infant period and appear gradually later, simultaneously with the diminution of the primitive reflexes. For example, the Landau reaction was considered not present at birth, the tonic labyrinthine reflex was present in 80% of normal infants by 2 weeks of age, and symmetric tonic neck righting appeared later than the infant period and disappeared in a 3- to 6-month period. Again, different postural reactions are used preferentially by different investigators, either as isolated

Table 3. Eliciting the postural reactions according to references [32] and [60]*

Reaction	Position	Method
Traction	Supine	Placing the examiner's index finger in the infant's hand and pulling the infant at a 45° angle with the examination bed
Horizontal suspension	Prone	Suspending the infant by placing the hands around the infant's thorax without providing support for the head or legs
Vertical suspension	Vertical	Placing both hands in the axillae, without grasping the thorax and lifting the infant straight up facing the examiner
Vojta response	Vertical	Suspension from the vertical to the horizontal position facing the examiner by placing both hands around the infant's thorax
Collis horizontal suspension	Prone	Placing one hand around the upper arm and the other around the upper leg and suspending the infant in the horizontal position parallel to the examination bed
Collis vertical suspension	Prone	Placing one hand around the upper leg and suspending the infant in the vertical position with head directed downwards
Peiper-Isbert vertical suspension	Prone	Placing the examiner's hands around each upper leg of the infant and suspending the infant in the vertical position with head directed downwards

* For normal responses at each month of the first year of life one, refer accordingly to [32]. An example of normal and abnormal responses at the age of 6 months is presented in Figure 1.

items or as part of a developmental scale or optimality score. For example, Haataja et al. [6] favor an optimality score, which focuses among others on vertical suspension, parachute reaction, arm protection, and lateral tilting, whereas Scherzer [21] finds clinically relevant—and uses systematically—neck righting, parachute or protective extension, and the Landau reaction. In one of the few review articles dealing with the neurologic examination of the infant, Fenichel [44] utilizes the traction response, vertical suspension, and the Landau reaction.

Early Diagnosis of Cerebral Palsy

As stated earlier, the evaluation of posture, muscle tone, primitive reflexes, and postural reactions is an integral part of the neurologic examination of the infant in the first year of life. Posture or muscle tone disturbances during the first 12 months of life in high-risk infants are not always prognostic of the later diagnosis; some of these infants are normally developed, whereas others have various types of cerebral palsy or developmental retardation without motor disturbance [47-49].

The same is true for motor milestones such as sitting, pulling to stand, and standing: as Blasco [26] states, they

represent the basis for formulating locomotor prognosis in individual patients with cerebral palsy; however, they do not contribute to an early diagnosis (i.e., in the first 6 months of life). In such cases, examination of primitive reflexes or postural reactions has been advocated to serve as a screening test for postural abnormalities, especially regarding cerebral palsy.

Infants with cerebral palsy have been known to demonstrate persistence of primitive reflexes or a delay in their disappearance [39]. Persistence of obligatory primitive reflexes beyond 12 months of age is an indicator of a poor prognosis regarding ambulation [39,50]. This early work has led the Kennedy group to develop a “Primitive Reflex Profile” to be used as a clinical research diagnostic tool [27]. Another step was to obtain normative data for nine primitive reflexes in 381 normal infants by documenting prospectively their sequential changes during the first 2 years of life [51], as well as to describe the evolution of the Primitive Reflex Profile for the preterm infant [25]. The clinical experience with the Primitive Reflex Profile and its contribution to an earlier diagnosis (6 to 8 months of life) were subsequently underlined by its developers, as well as other investigators [25,48]. This organized examination's schema has led several investigators like Futagi [30] and our group [31,33,34] to test and suggest separate and distinct patterns of the Primitive Reflex Profile, indicative of cerebral palsy, as well as of developmental retardation.

Combining the results of these studies with the pioneer work of Vojta [32], it emerges that early diagnostic clues concerning whether a high-risk infant will become normal at the age of 2 years are as follows: the presence of the suprapubic extensor reflex, the crossed extensor reflex, the Rossolimo reflex, and the heel reflex after 3 months; a positive Galant and asymmetric tonic neck reflex after 5 months; a positive palmar grasp reflex after 7 months; and a negative plantar grasp reflex after 3 months [30]. In a significant number of patients with spastic cerebral palsy, the Moro reflex cannot be elicited in the first months of life, appears subsequently in the fifth or even the seventh month, and is retained until the age of 11 months, supporting the hypothesis that the Moro reflex is blocked by certain inhibitory mechanisms at the first 3 to 5 months in children with spastic cerebral palsy and then starts being elicited, either because of central nervous system maturation or because of a physical therapy effect [34].

Last, but not least, in the chaos of reflexology, the presence of a combined extensor plantar response or Babinski response (i.e., dorsiflexion of the great toe with fanning of the remaining toes) was found to be a reliable prognostic clinical tool, which contributed to an earlier diagnosis of spastic cerebral palsy, already from the first month of life [33]. On the basis of these primitive reflexes, neurologically abnormal children could be diagnosed much earlier (at the first 3 months of life). Moreover, delay in the disappearance of the asymmetric tonic neck reflex, Moro, plantar grasp, and Galant reflexes is more

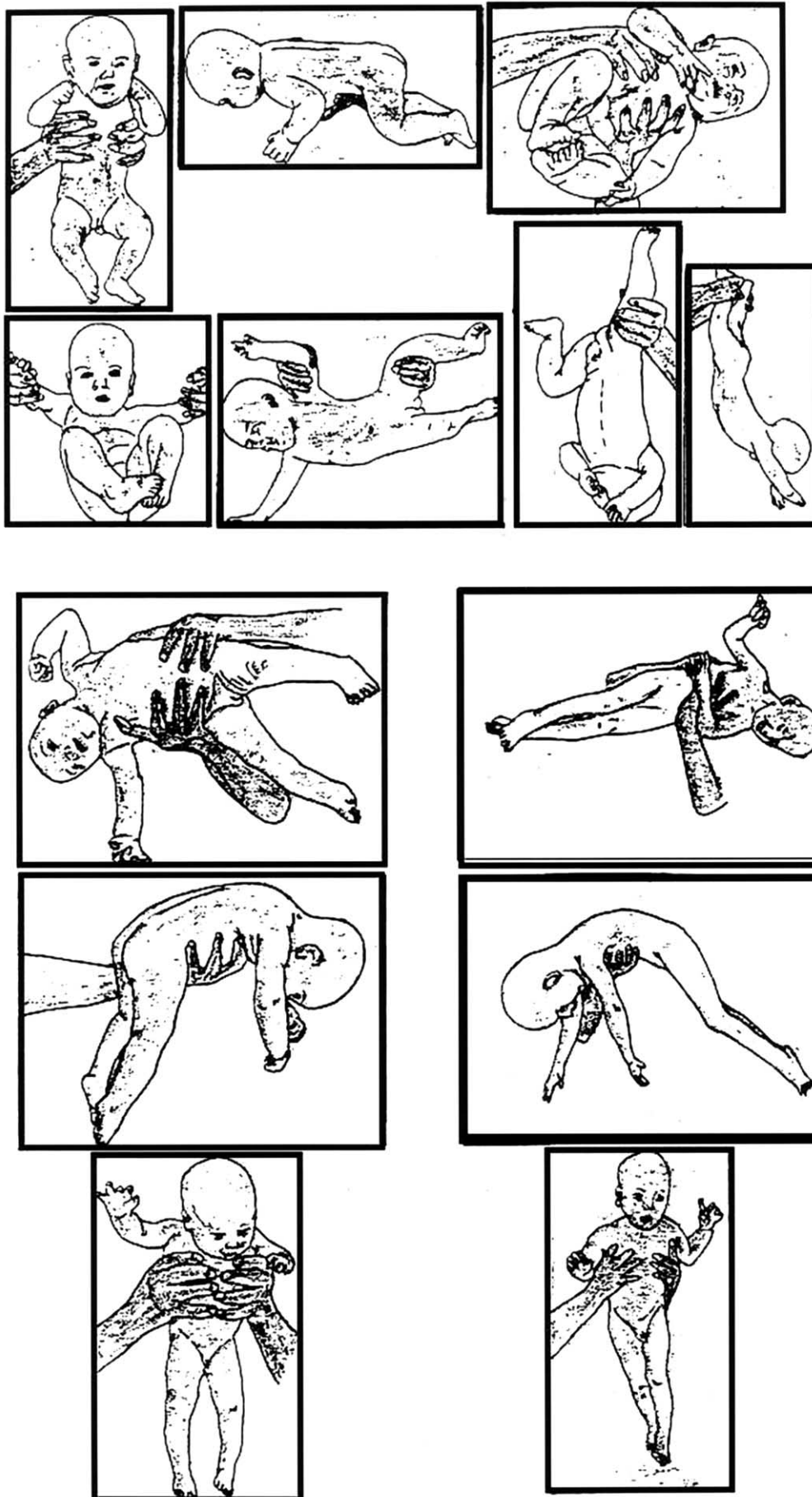


Figure 1. Upper half: Eliciting the seven postural reactions—normal response at the age of 6 months. From left up to right down corner: vertical suspension, horizontal suspension, Vojta response, traction response, Collis horizontal reaction, Collis vertical reaction, and Peiper-Isbert reaction. Lower half, left up to down: Abnormal Vojta response, horizontal suspension, and vertical suspension in suspected spastic cerebral palsy (age 6 months). Lower half, right up to down: The same postural reactions in fixed cerebral palsy (age 15 months). (From reference [60] with permission)

conspicuous among athetoid than spastic infants [30,31,34,52-54], whereas the presence of a Babinski response, as well as a Rossolimo, a crossed extensor, a suprapubic extensor, and a heel reflex is indicative of spastic cerebral palsy [30,31,34]. In fact, the combined examination of the reflexes mentioned earlier can clearly distinguish between spastic and athetoid cerebral palsy; however, the diagnosis of ataxic cerebral palsy, developmental retardation, or mixed cerebral palsy forms cannot be made on this basis alone.

In a considerable number of patients with spastic cerebral palsy, some of the above tested reflexes such as the Moro, the Galant, and the asymmetric tonic neck reflex could not be elicited in the first months of life, appeared subsequently in the second half of the first year of life, and were retained until the end of the first year, supporting the hypothesis that these primitive reflexes are blocked by certain inhibitory mechanisms at the first months of life in children with spastic cerebral palsy and then start being elicited, either because of central nervous system maturation or because of a physical therapy effect [31,34]. Their preservation in spastic cerebral palsy seems to be related to pyramidal tract involvement. However, the fact that these reflexes persist throughout the first year in almost all patients with athetoid cerebral palsy suggests that pathways other than pyramidal (likely related to basal ganglia circuits) are also involved in their retention in these patients.

The diagnostic relevance of the various postural reactions is variably recognized with limited data available. Bleck underlines the predictive value of failure to develop postural reactions such as the parachute reaction and equilibrium in standing [55]. Scherzer finds clinically relevant—and uses systematically—neck righting, parachute or protective extension, and the Landau reaction [21]. As a rule of thumb, Molnar [56] stated that normal disappearance of primitive reflexes and delayed disappearance of postural reactions are more characteristic of mental retardation. Mandich et al. [29] demonstrated a statistically significant relationship between tonic labyrinthine reflex in supine position at hospital discharge (37 weeks corrected age) and appearance of pull to sit and rolling at 8 months, between asymmetric tonic neck reflex at hospital discharge and rolling prone to supine and vice versa at 8 months, as well as between parachute reaction at 8 months and sitting without support at 12 months. In the same context, onset of independent walking occurred approximately 4 months after the appearance of parachute reaction in a prospective study of 190 normal infants [57].

Earlier studies, which have used the seven postural reactions according to Vojta, have concentrated on the prognostic reliability of postural reactions, especially regarding the classification of central coordination disturbance (i.e., a tentative diagnosis of postural abnormalities) in relation to the extent of abnormalities of postural reactions [32,58,59]. According to this classification, a very light central coordination disturbance was diagnosed

in infants with 1-3 abnormal postural reactions, a light central coordination disturbance in infants with 4-5 abnormal postural reactions, a moderate central coordination disturbance in infants with 6-7 abnormal postural reactions, and a severe central coordination disturbance in infants with 7 abnormal postural reactions and an abnormal muscle tone. Infants with a moderate or severe central coordination disturbance were, as expected, more prone to develop cerebral palsy (for an example see Fig 1); the original results of Vojta were subsequently confirmed by these study groups.

In a study from our institution [60], the profiles of postural reactions during the first year of life were analyzed prospectively in high-risk infants referred for neurodevelopmental examination (being exclusively neonatal intensive care units survivors). All examined high-risk infants carried a higher risk for neurodevelopmental abnormalities compared with previous studies. Taking into account that all infants with 5 or more abnormal postural reactions developed either cerebral palsy or developmental retardation, we suggested that all infants with 5 or more abnormal postural reactions should be considered being at risk for either cerebral palsy or developmental retardation. However, it should be the specific combination of postural reaction abnormalities which eventually can predict more accurately the type of neurologic impairment.

Primitive Reflexes in Adults

In adults, the clinical implication of a positive primitive reflex is a controversial issue. Its presence is believed to signify frontal lobe damage or upper motor neuron disease. It is generally considered as a marker of cortical disinhibition. The elicitation of these reflexes has been incorporated in the neurologic examination of patients with dementia or human immunodeficiency virus-infected patients [61,62]; they have been also reported as useful in the clinical assessment and diagnosis of various neurologic disorders such as Alzheimer's disease, schizophrenia, multiple sclerosis, Parkinson's disease, frontal lobe lesions, and hydrocephalus [63-66].

Assessment of General Movements

A new approach to neurologic assessment, based on observation of the spontaneous motility of fetuses, preterm and term infants, has been recently proposed by Prechtl et al. [14,15,67]. The central idea of this approach is that the observation of general movements, which are gross movements involving the entire body, is more reliable than the assessment of the incidence of specific isolated movements and can predict outcome in infants at risk. Although this method is quick and easy to perform, it requires training of the examiner to make an interpretation; moreover, standardized video equipment is required, something that makes its use uneasy in nonhospital environments. Last but not least, the "state" of the infant, an important

parameter for Prechtl from the beginning of his research in the 1960s, is crucial for the interpretation of the results; again, time constraints make it difficult for both examiners and parents to wait 1 or 2 hours to reach the desirable state of alertness.

Earlier studies have reported that the quality of general movements has good predictive value [15,67,68], contrary to that of earlier instruments available to date. Most of these studies examined mature infants at birth who were either term or >30 weeks gestation and included high-risk infants. Moreover, previous studies, which used repeated general movements assessment weekly until 6 months of age, suggested that the quality and presence of abnormal fidgety movements, usually observed by 2 to 4 months of age, are the most useful indicators of neurodevelopmental outcome [15,67,69]. Therefore it would not be practical for the daily clinical practice to perform weekly assessments over several months to identify the infants at risk for neurodevelopmental disability. In a recent study of Maas et al. [70], scoring general movement quality at term chronological age did not add to the power of the Prechtl test [8] to predict the neurologic and developmental outcomes at 2 years chronological age. Nevertheless, assessment of the general movements seems to be a promising diagnostic tool for the motor assessment of the infant-at-risk.

Conclusions

Although there are a considerable number of instruments dealing with the early diagnosis of motor abnormalities, the combined examination of primitive reflexes and postural reactions still has a place in the neurologic examination of the neonate or infant. It is quick and easy to perform, both in nonhospital environments and underdeveloped countries, where time and specific resources are limited, as well as in developed countries, since many developmental disorders such as cerebral palsy appear in nonrisk groups whereas others are not detected by metabolic screening programs. The combined examination should be considered by the child neurologist as a simple but predictive screening test for the early identification of infants at risk for either cerebral palsy or developmental retardation. In conjunction with the motor developmental milestones, the classic neurologic examination, neurodevelopmental evolution over time, and other subjective or objective clinical evidence supporting neurologic dysfunction (i.e., poor feeding and communication, disorder of muscle tone and posture, motor stereotypies, failure of the head to grow at the appropriate rate for age, and evaluation with standard developmental screening tests such as the Denver Developmental Scale [9]), the combined examination of primitive reflexes and postural reactions constitutes a solid basis for the evaluation of neonatal and infantile motor disorders [26,71].

References

- [1] **Menkes JH**, Sarnat HB, Moser FG. Introduction: Neurological examination of the child and infant. In: Menkes JH, Sarnat HB, eds. Textbook of child neurology, 6th ed. Philadelphia: Lippincott-Williams & Wilkins, 2000:1-32.
- [2] **Amiel-Tison C**. Neurological evaluation of the maturity of newborn infants. *Arch Dis Child* 1968;43:89-93.
- [3] **Bayley N**. Bayley Scales of Mental and Motor Development, as used in the Collaborative Perinatal Research Project. Bethesda, MD: National Institute of Neurological Diseases and Blindness, 1961.
- [4] **Brazelton T**, Nugent K. Neonatal Behavior Assessment Scale, 3rd ed. London: Mac Keith, 1995.
- [5] **Dubowitz LMS**, Dubowitz V, Mercuri E. The neurological assessment of the preterm and full-term infant, 2nd ed. London: Mac Keith, 1999.
- [6] **Haataja L**, Mercuri E, Regev R, et al. Optimality score for the neurological examination of the infant at 12 and 18 months of age. *J Pediatr* 1999;135:153-61.
- [7] **Reed H**. Review of Peabody developmental motor scales and activity cards. In: Mitchell J, ed. The ninth mental measurements yearbook. Lincoln: University of Nebraska Press, 1985:1119-32.
- [8] **Prechtl H**, Beintema D. Neurological examination of the full term infant. London: Heinemann, 1964.
- [9] **Frankenburg WK**, Dodds J, Archer P, Shapiro H, Bresnick B. The Denver II: A major revision and restandardization of the Denver Developmental Screening Test. *Pediatrics* 1992;89:91-7.
- [10] **Glascow F**, Byrne KE. The usefulness of the Battelle Developmental Inventory Screening Test. *Clin Pediatr* 1993;32:237-80.
- [11] **Leppert MLO**, Shank TP, Shapiro BK, Capute AJ. The Capute Scales: CAT/CLAMS-tool for the early detection of mental retardation and communicative disorders. *Ment Retard Devel Disabl Res Rev* 1998;4:14-19.
- [12] **Knobloch H**, Stevens F, Malone A. The Revised Developmental Screening Inventory. Houston, Texas: Gesell Developmental Test Materials, 1980.
- [13] **Dargassies SS**. Neurological development in the full term and premature neonate. New York: Excerpta Medica, 1997.
- [14] **Prechtl HF**. State of the art of a new functional assessment of the young nervous system. An early predictor of cerebral palsy. *Early Human Dev* 1997;24:1-11.
- [15] **Prechtl HF**, Eisenpieler C, Cioni G, Bos AF, Ferrai F, Sontheimer D. An early marker for neurological deficits after perinatal brain lesions. *Lancet* 1997;349:1361-3.
- [16] **Piper MC**, Pinnell LE, Darrah J, Maguire T, Byrne PJ. Construction and validation of the Alberta Infant Motor Scale (AIMS). *Can J Publ Health* 1992;83(Suppl. 2):S46-50.
- [17] **Morgan A**. Early diagnosis of cerebral palsy using a profile of abnormal motor patterns [Abstract]. *Dev Med Child Neurol* 1988; 30(Suppl. 57):12.
- [18] **Russell D**, Rosenbaum PL, Avery LM, Lane M. Gross Motor Function Measure (GMFM-66 and GMFM-68). User's manual. London: Mac Keith, 2002.
- [19] **Kaye L**, Whitfield MF. The eighth month movement assessment of infants as a prediction of cerebral palsy in high-risk infants [Abstract]. *Dev Med Child Neurol* 1988;30(Suppl. 57):11.
- [20] **Campbell S**, Osten E, Kolobe T, Fisher AG. Development of the test of infant motor performance. *Phys Med Rehabil Clin* 1993;4: 541-50.
- [21] **Scherzer AL**. Diagnostic approach to the infant. In: Scherzer AL, ed. Early diagnosis and interventional therapy in cerebral palsy, 3rd ed. New York: Marcel Dekker, 2000:49-94.
- [22] **Katelaar M**, Verneer A, Helders PJ. Functional motor abilities of children with cerebral palsy: A systematic literature review of assessment measures. *Clin Rehabil* 1998;12:369-80.
- [23] **Majnemer A**, Mazer B. Neurologic evaluation of the newborn infant: Definition and psychometric properties. *Dev Med Child Neurol* 1998;40:708-15.
- [24] **Gesell A**. Behavior patterns of fetal-infant and child with

evidence of innate growth factors. In: Hooker D, Hare CC, eds. Genetics and inheritance of neuropsychiatric patterns. Res Publ Assoc Res Nerv Ment Dis 1954;33:114-26.

[25] **Allen MC**, Capute AJ. The evolution of primitive reflexes in extremely premature infants. *Pediatr Res* 1986;20:1284-9.

[26] **Blasco P**. Primitive reflexes: Their contribution to the early detection of cerebral palsy. *Clin Ped* 1994;33:388-97.

[27] **Capute AJ**. Primitive Reflex Profile. Baltimore: University Park Press, 1978.

[28] **Gupta V**. Manual of developmental and behavioral problems in children. New York: Marcel Dekker, 1999:33-45.

[29] **Mandich M**, Simons CJR, Ritchie S, Schmidt D, Mullet M. Motor development, infantile reactions and postural responses of pre-term, at-risk infants. *Dev Med Child Neurol* 1994;36:397-405.

[30] **Futagi Y**, Tagawa T, Otani K. Primitive reflex profiles in infants: Differences based on categories of neurological abnormality. *Brain Dev* 1992;14:294-8.

[31] **Zafeiriou DI**, Tsikoulas IG, Kremenopoulos GM. Prospective follow-up of primitive reflex profiles in high-risk infants: Clues to an early diagnosis of cerebral palsy. *Pediatr Neurol* 1995;13:148-52.

[32] **Vojta V**. Die cerebralen Bewegungstoerungen im Kindesalter, 4te Auflage. Stuttgart: Ferdinand Enke Verlag, 1988.

[33] **Zafeiriou DI**, Tsikoulas I, Kremenopoulos G, Kontopoulos E. Plantar response profile of high-risk infants at the first year of life. *J Child Neurol* 1999;14:514-7.

[34] **Zafeiriou DI**, Tsikoulas I, Kremenopoulos G, Kontopoulos E. Moro reflex profile in high-risk infants at the first year of life [Letter]. *Brain Dev* 1999;21:216-7.

[35] **Paine R**. The evolution of infantile postural reflexes in the presence of chronic brain syndromes. *Dev Med Child Neurol* 1964;6:345-61.

[36] **Towen B**. Neurological development in infancy. London: William Heinemann and Philadelphia: JB Lippincott, 1976.

[37] **Holt KS**. Medical examination of the child with cerebral palsy. *Pediatr Ann* 1979;8:581-8.

[38] **Molnar GE**. Cerebral palsy: Prognosis and how to judge it. *Pediatr Ann* 1979;8:596-605.

[39] **Capute AJ**. Identifying cerebral palsy in infancy through study of primitive-reflex profiles. *Pediatr Ann* 1979;8:589-95.

[40] **Landau WM**. Clinical definition of the extensor plantar reflex. *N Engl J Med* 1971;285:1149-50.

[41] **Volpe JJ**. The neurological examination: Normal and abnormal features. In: Volpe JJ, ed. Neurology of the newborn, 4th ed. Philadelphia: WB Saunders, 2001:103-33.

[42] **Gingold MK**, Jaynes ME, Bodensteiner JB, Romano JT, Hammond MT. The rise and fall of the plantar response in infancy. *J Pediatr* 1998;133:568-70.

[43] **Landau WM**. Babinski's reflex, sign of. In: Adelman G, ed. Encyclopedia of neuroscience. Boston: Birkhauser, 1987:109-10.

[44] **Fenichel GM**. Neurological examination of the newborn. *Brain Dev* 1993;15:403-10.

[45] **Capute AJ**, Wachtel RC, Palmer FP, Shapiro BK, Accardo PJ. A prospective study of three postural reactions. *Dev Med Child Neurol* 1982;24:314-20.

[46] **Blasco PA**. Normal and abnormal motor development. *Pediatr Rounds* 1992;1:1-6.

[47] **Piper MC**, Mazer B, Silver KM, Ramsay M. Resolution of neurological symptoms in high-risk infants during the first two years of life. *Dev Med Child Neurol* 1988;30:26-35.

[48] **Burns YR**, O'Callaghan M, Tudehope DI. Early identification of cerebral palsy in high risk infants. *Aust Paediatr J* 1989;25:215-9.

[49] **PeBenito R**, Santello MD, Faxas TA, Ferretti C, Fisch CB.

Residual developmental disabilities in children with transient hypertonicity in infancy. *Pediatr Neurol* 1989;5:154-60.

[50] **Taft LT**. Early recognition of cerebral palsy. *Pediatr Ann* 1973;2:30-46.

[51] **Capute AJ**, Palmer FB, Shapiro BK, Wachtel RC, Ross A, Accardo PJ. Primitive reflex profile: Quantification of primitive reflexes in infancy. *Dev Med Child Neurol* 1984;26:375-83.

[52] **Yokochi K**, Shimabukuro S, Kodama M, Kodama K, Hosoe A. Motor function of infants with athetoid cerebral palsy. *Dev Med Child Neurol* 1993;35:909-16.

[53] **Futagi Y**, Suzuki Y, Goto M. Clinical significance of plantar grasp response in infants. *Pediatr Neurol* 1999;20:111-5.

[54] **Zafeiriou DI**. Plantar grasp reflex in high-risk infants at the first year of life. *Pediatr Neurol* 2000;22:75-6.

[55] **Bleck EE**. Locomotor prognosis in cerebral palsy. *Dev Med Child Neurol* 1975;17:18-25.

[56] **Molnar GE**. Motor deficit of retarded infants and young children. *Arch Phys Med Rehab* 1974;55:393-8.

[57] **Jaffe M**, Kugelman A, Tirosh E, Cohen A, Tal Y. Relationship between the parachute reactions in standing and walking in normal infants. *Pediatr Neurol* 1994;11:38-40.

[58] **Suzuki J**, Yamori Y, Kanda T, Fukase T. A follow-up study of cerebral coordination disturbance (4)—Reliability of postural reaction. *Brain Dev* 1981;3:188.

[59] **Imamura S**, Sakuma K, Takahashi T. Follow-up study of children with cerebral coordination disturbance (CCD, Vojta). *Brain Dev* 1983;5:311-4.

[60] **Zafeiriou DI**, Tsikoulas IG, Kremenopoulos GM, Kontopoulos EE. Using postural reactions as a screening test to identify high-risk infants with cerebral palsy: A prospective study. *Brain Dev* 1998;20:307-11.

[61] **Howlett WP**, Nkya WM, Kvale G, Milssen S. The snout and palmmental reflexes in HIV disease in Tanzania. *Acta Neurol Scand* 1995;91:470-6.

[62] **Orefice G**, Carrieri PB, Troisi E, et al. Three primitive reflexes in HIV-1-infected individuals: A possible clinical marker of early central nervous system involvement. *Acta Neurologica* 1993;15:409-15.

[63] **Nolan M**. Introduction to the neurologic examination. Philadelphia: FA Davis, 1996.

[64] **Thomas RJ**. Blinking and release reflexes: Are they clinically useful? *J Am Geriatr Soc* 1994;42:609-13.

[65] **Pattern JP**. Neurological differential diagnosis, 2nd ed. New York: Springer, 1996.

[66] **Franssen EH**, Souren LE, Torossian CL, Reisberg B. Utility of developmental reflexes in the differential diagnosis and prognosis of incontinence in Alzheimer's disease. *J Geriatr Psychiatry Neurol* 1997;10:22-8.

[67] **Cioni G**, Ferrari F, Einspieler C, Paolicelli PB, Barbani MT, Prechtel HFR. Comparison between observation of spontaneous movements and neurologic examination in preterm infants. *J Pediatr* 1997;130:704-11.

[68] **Hadders-Algra M**, Klip-Van den Nieuwendijk AWJ, Martijn A, Van Eykern LA. Assessment of general movements: Towards a better understanding of a sensitive method to evaluate brain function in young infants. *Dev Med Child Neurol* 1997;39:89-99.

[69] **Nijhuis JG**, Prechtel HFR, Martin CB, Bots RSGM. Are there behavioral states in the human fetus? *Early Hum Dev* 1982;6:177-95.

[70] **Maas YGH**, Mirmiran M, Hart AAM, Koppe JG, Ariagno RL, Spekrijse H. Predictive value of neonatal neurologic tests for developmental outcome of preterm infants. *J Pediatr* 2000;137:100-6.

[71] **Ashwal S**. Historical aspects of the neonatal neurological examination: Why child neurologists are not "little" adult neurologists. *J Hist Neurosci* 1994;3:1-22.